

CASE REPORT

A case of aspergillosis outbreak in a broiler duck farm in Kelantan, Malaysia

Eric Lim Teik Chung¹, Mohd Farhan Hanif Reduan², Muhammad Luqman Nordin³, Faez Firdaus Jesse Abdullah⁴, Nurul Huda Mohd Zairi⁵, Nur Zul Izzati Mohd Rajdi³, Intan Noor Aina Kamaruzaman², Nurshahirah Shaharulnizim³

¹Department of Animal Science, Faculty of Agriculture, Universiti Putra Malaysia, Selangor, Malaysia

²Department of Paraclinical Studies, Faculty of Veterinary Medicine, Universiti Malaysia Kelantan, Kota Bharu, Malaysia

³Department of Clinical Studies, Faculty of Veterinary Medicine, Universiti Malaysia Kelantan, Kota Bharu, Malaysia

⁴Department of Veterinary Clinical Studies, Faculty of Veterinary Medicine, Universiti Putra Malaysia, Selangor, Malaysia

⁵Department of Veterinary Services Malaysia, Federal Government Administration Centre, Putrajaya, Malaysia

ABSTRACT

Objective: This case report aims to discuss the veterinary approach taken to control a case of aspergillosis outbreak on a duck farm.

Materials and Methods: A broiler duck farm with a population of 900 Muscovy ducks was having a complaint of a 5% mortality rate in their 3-week-old ducklings. Upon presentation, 10% of the ducks appeared to be listless, dyspneic, ruffled feathers, and cyanotic. Postmortem examination of the dead birds was conducted. The collected samples were subjected to isolation and identification of the associated *Aspergillus fumigatus* under the microscope using the scotch tape method.

Results: Postmortem examination revealed whitish to creamy caseous nodules in the lungs, thoracic air sacs, gizzard, proventriculus, and intestines. Granuloma lesions and infiltration of inflammatory cells were observed in the lung and liver tissues. As for therapeutic management, all ducks were treated with copper sulfate, erythromycin, and multivitamins as the fungicide, antibiotic, and supplement, respectively, via drinking water.

Conclusion: There is no effective treatment for Aspergillosis as the spores are difficult to destroy completely. Nonetheless, the disease can be controlled and prevented effectively with proper farm sanitation and providing a suitable feed storage environment to inhibit the growth of this opportunistic fungus.

ARTICLE HISTORY

Received June 03, 2020

Revised July 16, 2020

Accepted July 31, 2020

Published November 18, 2020

KEYWORDS

Aspergillosis; *Aspergillus fumigatus*;
Clinical diagnosis: Prevention,
Treatment



This is an Open Access article distributed under the terms of the Creative Commons Attribution 4.0 Licence (<http://creativecommons.org/licenses/by/4.0>)

Introduction

In Asia, duck products are top-rated and highly demanded among producers and consumers. Ducks occupy an important position next to the chicken industry in Malaysia. This is because Malaysia remains one of the top poultry meat consumer countries behind the United States and Israel [1]. To date, the self-sufficiency level of poultry meat in Malaysia is at 98.2%, with per capita poultry meat consumption of 52.0 kg, and this includes broiler duck [2]. According to the Federation of Livestock Farmer's Associations of Malaysia, the production of ducks is estimated at 28.56 million, and 7.25 million are exported live to Singapore. Currently, there

are 199 registered broiler duck farms in the country, with Pekin, Muscovy, and Mullard being the common breeds reared by these farms [3]. These ducks are commonly reared extensively on ex-mining ponds together with simple housing and facility, such as a wooden shed, without practicing proper biosecurity protocols. The condition is usually worsened with improper husbandry management, which is commonly reported in small and medium-scale farms.

Saprophytes from the soil, such as *Aspergillus* spp., are omnipresent in the environment and grow on organic matter in warm and humid environments [4]. For this reason,

Correspondence Mohd Farhan Hanif Reduan ✉ farhan.h@umk.edu.my 📧 Department of paraclinical Studies, Faculty of Veterinary Medicine, Universiti Malaysia Kelantan, Kota Bharu, Malaysia.

How to cite: Chung ELT, Reduan MFH, Nordin ML, Abdullah FFJ, Zairi NHM, Mohd Rajdi NZI, Kamaruzaman INA, Shaharulnizim N. A case of aspergillosis outbreak in a broiler duck farm in Kelantan, Malaysia. *J Adv Vet Anim Res* 2020; 7(4):692–697.

healthy ducks are often exposed to fungal spores regularly without showing any clinical sign. When the birds are immunocompromised, opportunistic organisms such as *Aspergillus fumigatus*, *Aspergillus flavus*, *Aspergillus niger*, *Aspergillus glaucus*, and *Aspergillus terreus* may infect the animals. Among these fungi, *Aspergillus fumigatus* is the most common and non-contagious fungus causing Aspergillosis or respiratory disease in ducks compared to other poultries [5]. Additionally, ducks, especially ducklings, are 200 times more susceptible than chickens [6]. The disease develops through inhalation of conidia or fungal spores into the respiratory tract, thus colonizing the lung tissues and inducing granulomas. Aflatoxins, produced by this fungus, will then be disseminated to the other tissues, like the brain, pericardium, bone marrow, kidney, and other soft tissues, causing severe inflammation and systemic failure [7].

As a result, the aflatoxins produced by this fungus have a severe economic impact on the duck industry as this toxin causes harmful effects to the growth performance, feed efficiency, and health problems, such as liver and kidney damage [5]. Owing to the tropical conditions in Malaysia [8], ducks are more vulnerable to becoming infected with this toxin. The occurrence of Aspergillosis is also aggravated when ducks are in stress due to inadequate ventilation, poor sanitation, low feed quality, improper feed storage, vitamin deficiency, and prolonged use of certain antibiotics or steroids as a result of concurrent infection and illness [9]. Among these predisposing factors, inadequate ventilation and improper feed storage contribute significantly to the disease outbreak by increasing bird exposure to fungal spores present in the feed [10–12]. Therefore, this case report highlights a case of aspergillosis outbreak in small-scale broiler duck farms due to improper husbandry management, including the diagnostic approach and therapeutic management.

History

A broiler duck farm was having a complaint of a high mortality rate in their 3-week-old Muscovy ducklings. A total of 900 ducks were raised extensively on an ex-mining pond. All ducks were fed with the own feed formulation consisting of sago, rice, duck pellet, and coconut, while clean tap water was given *ad libitum*. Feed materials were stored in an enclosed shed but without proper ventilation. Vaccination and deworming programs were not practiced on the farm. The farm owner reported that the ducks started dying since the first week, and the number of deaths was increasing in every week. The mortality rate was 5% at the time of presentation.

Clinical presentation

Upon clinical investigation, 10% of the affected birds were observed to be listless, dyspneic, and ruffled feathers,

whereas some ducks were also having cyanotic bills (Fig. 1). Postmortem was conducted on fresh carcasses from the same day to determine the cause of death. The postmortem findings revealed whitish to cream caseous nodules at different locations, such as the lungs, thoracic air sacs, gizzard, proventriculus, and intestines (Fig. 2). The lungs were severely affected with diffused caseous nodules causing granulomatous pneumonia. In addition, the liver appeared to be enlarged with generalized discoloration. Upon cross-sectioning, blood was oozing out from the cut surface, indicating liver congestion (Fig. 3).

The differential diagnoses at that time were mycotoxicosis, cryptococcosis, and avian tuberculosis. Mycotoxicosis is a disease caused by the metabolites produced by fungal species, such as *Aspergillus* spp. On the contrary, cryptococcosis is another crucial fungal disease in duck acquired by inhalation of soil contaminated with *Cryptococcus neoformans*. Avian tuberculosis caused by *Mycobacterium avium* is a chronic wasting disease and is characterized by nodular lesions present in the air sacs and lungs of infected birds. Feed, organs, and lesion samples were collected for further diagnostic workup.

Diagnostic workup

Bacterial culture was conducted on the feed and organ samples collected. *Staphylococcus* spp. and *Escherichia coli* were isolated and identified from the air sacs and tracheal swabs, respectively. Their presence may be attributed to contamination during sampling, while no microbial growth was observed in the feed, lungs, liver, and caseous nodules. Additionally, these samples were also subjected to fungal culture and identification using Sabouraud's dextrose agar. The lungs, liver, tracheal swab, caseous nodules, and the feed samples exhibited a whitish, gray to green center with a puffy growth appearance after 48 h of post-incubation. Using the scotch tape method [13], *A. fumigatus* was identified based on the microscopic characteristics of conidiophore, vesicle, metulae, phialides, and conidia (Fig. 4).

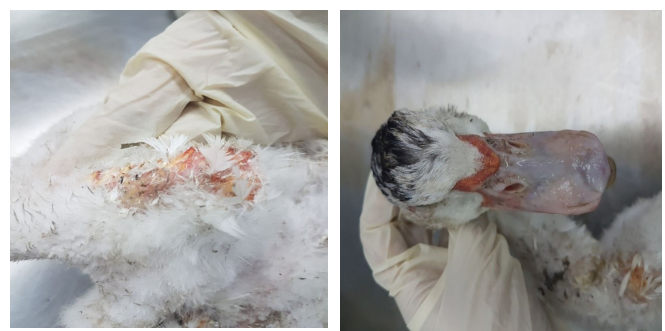

Figure 1. Duck with ruffled feathers at the ventral abdomen (left). The dorsal part of the bill appears congested and bluish (right).

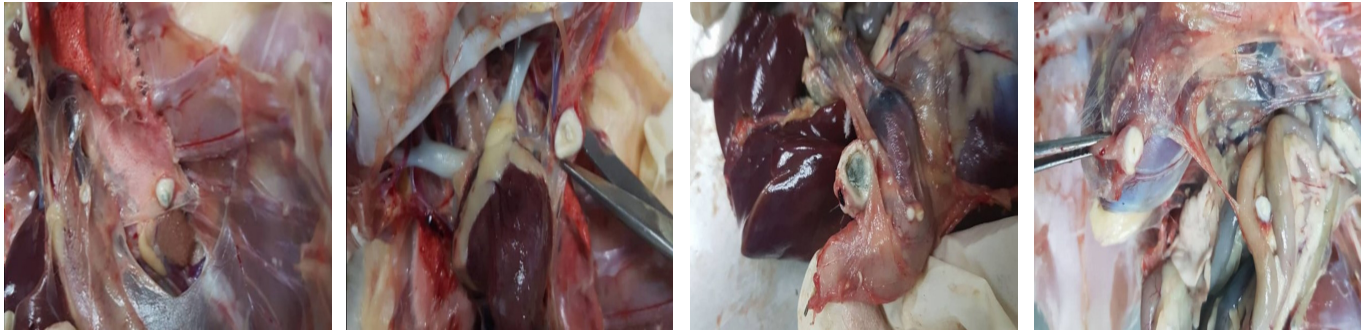


Figure 2. Presence of whitish to cream caseous nodules at different locations, such as the lungs (top left), thoracic air sacs (top right), gizzard (bottom left), proventriculus, and intestines (bottom right).

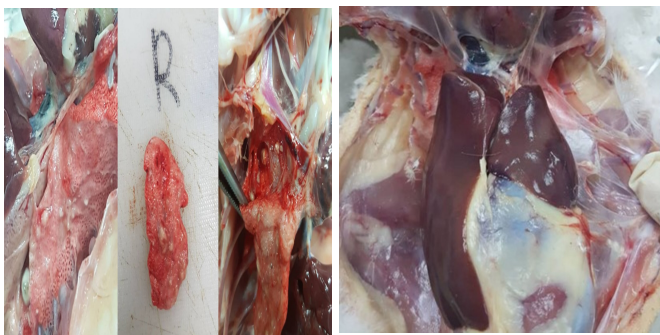


Figure 3. The lungs (left) and the liver (right) appear to be granulomatous and congested, respectively.

Besides, histopathological examination was conducted on the lungs and liver using Hematoxylin and Eosin (H&E) staining [13,14]. The lung tissue demonstrated few granuloma lesions circumscribed with fibrous tissue. The circular lesion of the granulomas was space-occupying, which compressed the adjacent lung tissue causing both atelectasis and emphysema, leading to dyspnea in the ducks. At higher magnification, the presence of hyphae and spores can be visualized. This was confirmed using the periodic acid-Schiff (PAS) staining technique [15]. On the other hand, the liver tissue was observed to be congested with red blood cells present in the central portal vein. There was also infiltration of polymorphonuclear cells and loss of hepatocyte architecture of the liver tissue (Fig. 5).

Treatment and prevention

The duck farm was diagnosed with Aspergillosis caused by *A. fumigatus* based on the clinical evaluation and diagnostic workup. As a result, the ducks were treated with copper sulfate (Ema-Sol™; at 3.75 ml/l) in drinking water for 10 days as a fungicide. 1.5 gm/l of erythromycin was also administered via drinking water for 7 days to treat and prevent secondary bacterial infection. Moreover, multivitamins (Stresspac®; at 0.5 gm/l) were supplied

in the drinking water as vitamin and electrolyte supplementation. The duck farm owner was advised to disinfect the farm with glutaraldehyde (at 30% w/v) and practice proper sanitation and strict biosecurity procedure of the farm. Furthermore, moldy feed needed to be removed, and new feed needed to be stored in an appropriate facility and environment to prevent fungal growth.

Discussion

Aspergillosis is one of the central problems of the poultry industry in the tropics, which could ultimately affect the production performance attributable to the reduction of feed intake and mortality due to multiple organ failure. The disease is induced by the ingestion of mycotoxin-contaminated feed produced by different fungal species. The type of fungal growth mainly depends on the geographical location with different environmental temperatures and relative humidity [16]. In this case, *Aspergillus* spp., known as storage fungi, increases in the conditions of relatively high humidity and temperature and produces aflatoxins. All poultry species are susceptible to aflatoxins, especially young ducks [6].

Nonetheless, according to Bibu [17], case reporting of fungal infection in adult ducks are usually rare. This could be either attributable to unreported cases due to the low mortality or was reported as another severe disease that causes significantly higher mortality. This is because aflatoxins are known to be hepatotoxic as well as immunosuppressing, leading to secondary infection [18]. In line with the findings of this case report, Mondal et al. [19] have reported that feed samples containing aflatoxins even in the smallest quantity, ranging from 20 to 30 ppb, were detrimental to ducks, causing hepatotoxicity.

The clinical signs of Aspergillosis observed in the birds are determined mostly by the number of spores inhaled into the body but can typically be reflected as a disease of the respiratory tract that invades the trachea, air sacs, lungs, as well as the central nervous system (CNS). Patisson et

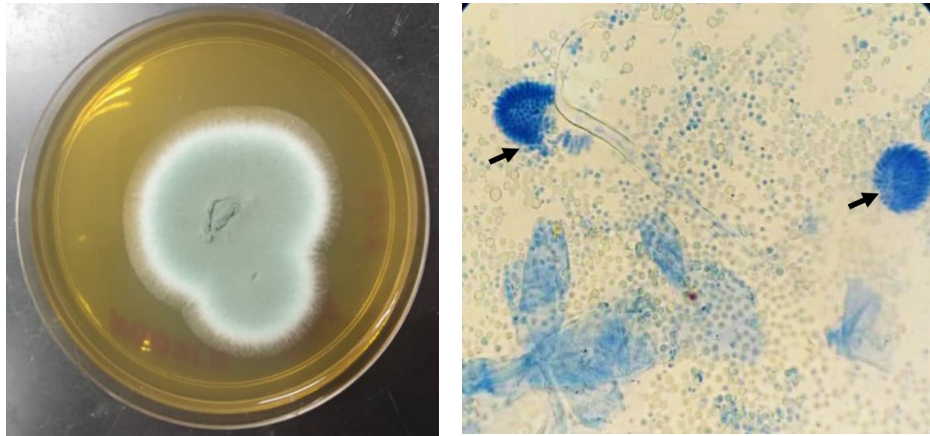


Figure 4. All the cultured samples have the same colony morphology, a puffy white colony with a green to gray center (left). Under a 10x microscopic examination with lactophenol cotton blue staining, flask-shaped conidiophores (arrow) are observed (right).

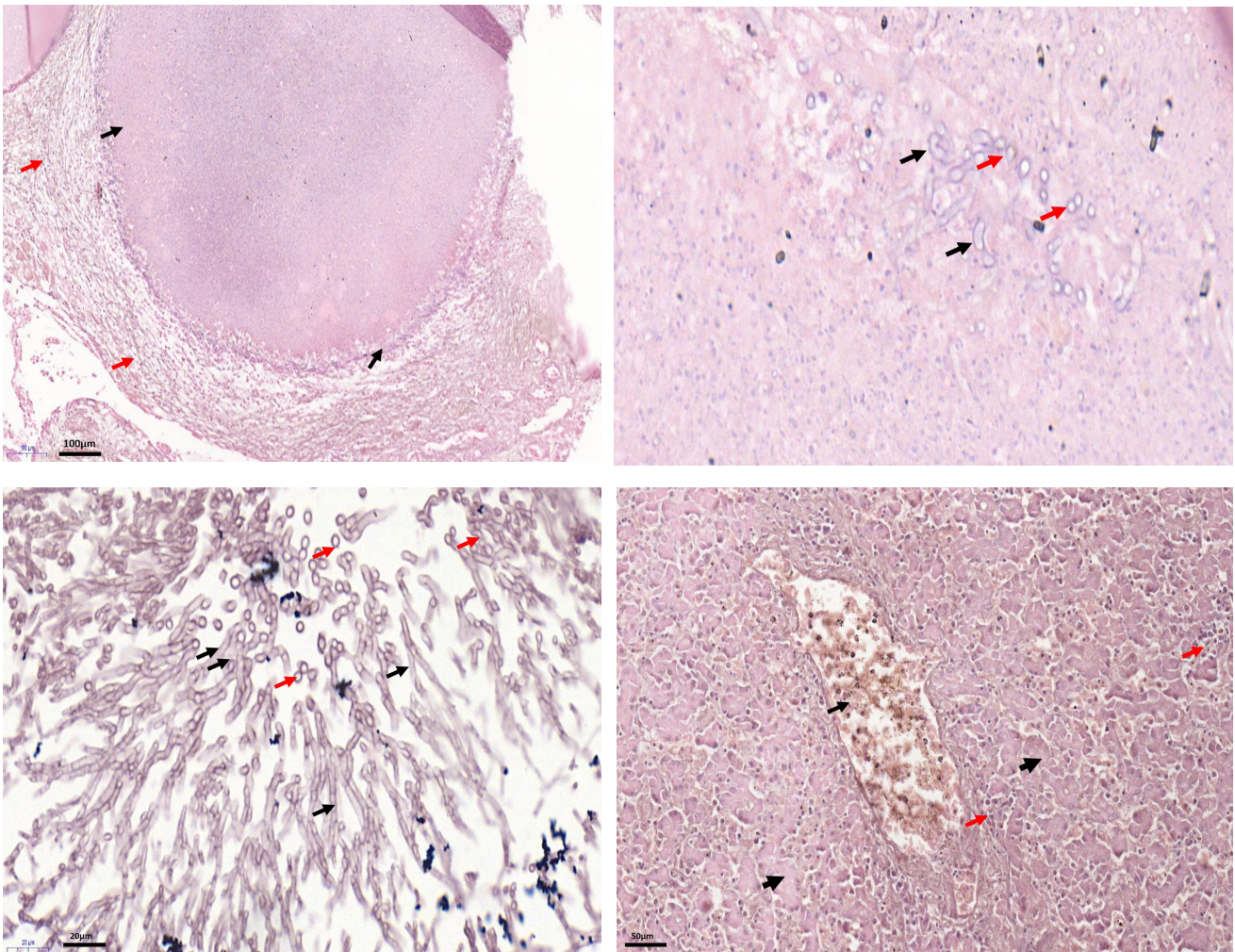


Figure 5. Presence of granulomas in the lung (black arrow) surrounded with fibrous lining causing atelectasis and emphysema (red arrow) (top left). Under a 60x microscopic examination, the presence of hyphae (black arrow) and spores (red arrow) can be visualized (top right). The hyphae (black arrow) and spores (red arrow) are more evident with PAS staining (bottom left). Congestion in the central portal vein (black arrow), infiltration of polymorphonuclear cells (red arrow), and loss of hepatocyte architecture of the liver (arrowhead) (bottom right).

al. [20] stated that diffuse lower respiratory tract diseases, syringeal granulomas, and focal CNS granulomas, particularly in the brain, are the three general presentations of Aspergillosis. Within the first few days of infection, the affected birds will show rapid and difficult breathing with an open mouth caused by continuous obstruction of the airway. Birds that survive may become dull, inappetence, and anorexic. Ocular swelling, blindness, and torticollis can be observed in the later stage. However, some birds may remain subclinically affected and later slowly develop respiratory signs when they become immunocompromised. Infected birds typically exhibit mortality in two phases [9]. During the first 1–3 weeks of age, acute respiratory disease causes 5%–50% mortality, as described in this case report. Other critical signs include vomiting, depression, cyanotic, hemorrhage, and icterus. Subacute outbreaks are more usual with unthriftiness, weakness, anorexia, reduced growth and feed efficiency, and sudden death. As shown in this case report, higher mortality was observed as the ducks grow because of the increasing body weight, which places demands on the reduced functional capacity of the affected lungs [21]. Usually, surviving birds develop chronic respiratory diseases of up to 5% mortality due to pulmonary compromise, ruffled feathers, change in vocalization, ascites, blindness, or neurological fungal metastasis [5].

Aspergillosis cases in birds are primarily diagnosed based on postmortem findings of white caseous nodules in the lungs or air sacs and other visceral organs. However, the clinical diagnosis of Aspergillosis is challenging [22]. Similar to this case report, the white to yellow plaques and nodules with different diameters were found in the trachea, lungs, air sacs, liver, intestines, and sometimes the brain [4]. Supporting this, granuloma formation was located in the brains of chickens and other wild birds [23] but not in this case report because no nervous signs were observed in the ducks, and probably the disease was still at the early phase. Additionally, organs, especially the lungs, can be subjected to further histopathology examination to confirm the case of Aspergillosis. Sultana et al. [24] stated that congestion of pulmonary and perialveolar blood vessels, perivascular edema of the lung, and disseminated granulomatous foci in the lung and air sacs, as well as infiltration of heterophils, lymphocytes, and macrophages, could be observed microscopically. Besides, fatty changes, cloudy swelling, necrosis, and infiltration of red blood cells are cardinal signs of the liver tissue [19], which agree with the findings of the present study. *Aspergillus fumigatus* culture and identification of this case report further strengthen the final diagnosis of Aspergillosis. The identification was based on the microscopic characteristics of conidiophore, vesicle, metulae, phialides, and conidia [25]. Agreeing to Kahn and Line [20], hematology and biochemistry could

also be used as an alternative but not a confirmatory diagnostic tool for the diagnosis of Aspergillosis. The specific laboratory changes include increased aspartate aminotransferase, alanine aminotransferase, and alkaline phosphatase. Other features are hypothermia, prolonged prothrombin and activated partial thromboplastin times, hyperbilirubinemia, hypocholesterolemia, hypoalbuminemia, and variable thrombocytopenia, which are associated with liver damage.

Aspergillosis treatment includes the use of a single or a combination of systemic antifungal agents, such as itraconazole, ketoconazole, clotrimazole, miconazole, fluconazole, and Amphotericin B [24]. However, medication against fungal infection is not usually practical because the drugs are unable to penetrate the fungus surrounded by the inflammatory response of the host. As presented in this case report, the disease has a poor prognosis; hence, supportive treatments are only given according to clinical symptoms to prevent further loss [9]. Even though prevention and avoidance are the best ways to control Aspergillosis, natural contamination of raw material with *A. fumigatus* is sometimes unavoidable. Thus, toxins present in feeds can be inactivated effectively using either physical or chemical techniques. Feed additives such as toxin binders have also been reported to prevent aspergillosis outbreak in poultries [17]. Hydrated sodium calcium aluminosilicates minimize the absorption and effects of aflatoxins when these are fed to pigs or poultries (at 5 kg/ton of feed). In comparison, other adsorbents such as sodium bentonites and polymeric glucomannans have demonstrated variable but modest efficacy for reducing aflatoxin residues in poultry and dairy cattle industries [26].

Conclusion

It is concluded that the *A. fumigatus* outbreak in this study happened due to the hot and humid environment in Malaysia. The situation is worsened in case of improper sanitation, mismanagement, and unsuitable feed storage on the farm. There is no effective treatment for the disease, whereas prevention and avoidance are the best ways of controlling it. Aspergillosis has zoonotic implications and can be transmitted to humans through the handling of infected birds and livestock, the inhalation of spores from infected feed and litter, inadequate hygiene, and low hygienic status.

Acknowledgment

The authors appreciate the staff of the Bacteriology and Histopathology Laboratory of the Universiti Malaysia Kelantan for their technical assistance during the handling of this case.

Conflict of interest

The authors declare that there is no conflict of interest.

Authors' contribution

Mohd Farhan Hanif Reduan, Nurul Huda Mohd Zairi, Muhammad Luqman Nordin, and Intan Noor Aina Kamaruzaman attended to and diagnosed the disease. Eric Lim Teik Chung and Faez Firdaus Abdullah Jesse, Nur Zul Izzati Mohd Rajdi, and Nurshahirah Shaharulnizim conceived and drafted the manuscript. Mohd Farhan Hanif Reduan and Eric Lim Teik Chung reviewed the manuscript. All the authors read and approved the manuscript for final publication.

References

- [1] Chung ELT, Kamalludin MH, Jesse FFA, Reduan MFR, Loh TC, Idrus Z. Effect of monocalcium phosphate supplementation on the growth performance, carcass characteristic, gut histomorphology, meat and bone quality of broiler chickens. *J Trop Agric Sci* 2019; 42(4):1237–50.
- [2] Department of Statistics Malaysia. (2019). Supply and utilization accounts selected agricultural commodities, Malaysia 2013-2017. Available via https://www.dosm.gov.my/v1/index.php?r=column/cthemByCat&cat=164&bul_id=ZE12RXM2SD-M1eGRxRXR3bU0xRThrUT09&menu_id=Z0VTZGU1UHBUT1VJM-FlpaXRRR0xpdz09 (Accessed 01 July 2020)
- [3] Department of Veterinary Services Malaysia. (2019). Available via [http://www.dvs.gov.my/dvs/resources/user_1/2019/BP/PerangkaanTernakan20182019/1\)_Malaysia_Perangkaan_Ternakan.pdf](http://www.dvs.gov.my/dvs/resources/user_1/2019/BP/PerangkaanTernakan20182019/1)_Malaysia_Perangkaan_Ternakan.pdf) (Accessed 01 July 2020).
- [4] Shoukat S, Wani H, Jeelani R, Ali U, Ali M. An overview of avian Aspergillosis. *Int J Avian Wildl Biol* 2018; 3(3):215–6; <https://doi.org/10.15406/ijawb.2018.03.00088>
- [5] Mondal D, Sahoo SK. Prevalence of duck hepatitis in an experimental farm in Bhubaneswar. *Indian J Anim Health* 2018; 57:87–92; <https://doi.org/10.36062/ijah.57.1.2018.87-92>
- [6] Bintvihok A. Controlling aflatoxin danger to duck and duck meat. *World Poult* 2001; 17(11):18–20.
- [7] Kunkle RA, Rimiler RB. Pathology of acute aspergillosis in Turkeys. *Avian Dis* 1996; 40(4):875–86; <https://doi.org/10.2307/1592312>
- [8] Chung ELT, Nayan N, Kamalludin MH, Alghirani MM, Jesse FFA, Kassim NA, et al. The effects of alkaline and rainwater on the production and health performance of commercial broilers under tropical conditions. *Thai J Vet Med* 2020; 50(1):53–61; <https://doi.org/10.1080/00071668.2020.1817327>
- [9] Girma G, Abebaw M, Zemene M, Mamuye Y, Getaneh G. A review on aspergillosis in poultry. *J Vet Sci Technol* 2016; 7(6):382; <https://doi.org/10.4172/2157-7579.1000382>
- [10] Arné P, Thierry S, Wang D, Deville M, Loc'h L, Desoutter A, et al. *Aspergillus fumigatus* in poultry. *Int J Microbiol* 2011; 2011:1–14; <https://doi.org/10.1155/2011/746356>
- [11] Munir MT, Rehman ZU, Shah MA, Umar S. Interactions of *Aspergillus fumigatus* with the respiratory system in poultry. *World's Poult Sci J* 2017; 73(2):321–36; <https://doi.org/10.1017/S0043933917000022>
- [12] Beernaert LA, Pasmans F, Van Waeyenberghe L, Haesebrouck F, Martel A. Aspergillus infections in birds: a review. *Avian Pathol* 2010; 39(5):325–31; <https://doi.org/10.1080/03079457.2010.506210>
- [13] Reduan FH, Shaari RM, Sayuti NSA, Mustapha NM, Bakar MZA, Sithambaram S, et al. Acute and subacute dermal toxicity of ethanolic extract of *Melastoma malabathricum* leaves in sprague-dawley rats. *Toxicol Res* 2020; 36:203–10; <https://doi.org/10.1007/s43188-019-00013-5>
- [14] Hematoxylin and Eosin (H&E) Staining Protocol. Available via http://www.ispybio.com/search/protocols/Haematoxyline+Eosine+staining_1.htm (Accessed 01 July 2020)
- [15] Periodic Acid Schiff (PAS) Staining protocol. Available via http://www.ihcworld.com/_protocols/special_stains/pas.htm (Accessed 01 July 2020)
- [16] Federation of Livestock Farmers' Association of Malaysia. Available via <http://www.flfam.org.my/index.php/industry-info/the-poultry-industry/duck-production> (Accessed 01 July 2020)
- [17] Bibu KJ. Aflatoxicosis in white pekin duck. *Vet World* 2011; 4(5):215. <https://doi.org/10.5455/vetworld.2011.215>
- [18] FAO. Poultry development review. FAO, Rome, Italy, 2013.
- [19] Mondal D, Mukhopadhyay SK, Sahoo SK. Necropsy findings of carcasses and histopathology of liver in aflatoxicosis epitootics of ducks. *J Vet Anim Res* 2018; 1(2):203.
- [20] Patisson M, McMullin P, Bradbury J, Alexander D, Jordan F. Poultry disease. 6th edition, Elsevier Limited, Saunders, London, UK, 2008.
- [21] Vegad JL. Poultry diseases: a guide for farmers and poultry professionals. 2nd edition, International Book Distributing Co., Lucknow, India, 2005.
- [22] Olias P, Hauck R, Windhaus H, van der Grinten E, Gruber AD, Hafez HM. Articular aspergillosis of hip joints in turkeys. *Avian Dis* 2010; 54:1098–101; <https://doi.org/10.1637/9482-923210-DIGEST.1>
- [23] Hoppes S, Gurfield N, Flammer K, Colitz C, Fisher P. Mycotic keratitis in a blue-fronted amazon parrot (*Amazona aestiva*). *J Avian Med Surg* 2010; 14:185–9; [https://doi.org/10.1647/1082-6742\(2000\)014\[0185:MKIABF\]2.0.CO;2](https://doi.org/10.1647/1082-6742(2000)014[0185:MKIABF]2.0.CO;2)
- [24] Sultana S, Rashid SMH, Islam MN, Ali MH, Islam MM, Azam MG. Pathological investigation of avian Aspergillosis in commercial broiler chicken at Chittagong district. *Int J Innov Appl Stud* 2015; 10:366–76.
- [25] Diba K, Kordbacheh P, Mirhendi S, Rezaie S, Mahmoudi M. Identification of *Aspergillus* species using morphological characteristics. *Pak J Med Sci* 2007; 23(6):867.
- [26] Kahn CM, Line S. The merck veterinary manual. 9th edition, Merial, Lyon, France, 2005.